

L3-4 DISC HERNIATION IN 68 YEAR OLD MAN WHO IS TOLD TO HAVE SURGERY BUT IS MANAGED SUCCESSFULLY WITH COX® TECHNIC

HISTORY & EXAMINATION

This 68-year-old white male is seen for the chief complaint of left anterior thigh pain, weakness of the quadriceps muscle, and difficulty sleeping due to the pain. The pain is listed as an 8 on a VAS scale. This pain started approximately three weeks previously for no apparent reason, and he sought care from his family doctor who ordered the MRI shown in figures 1 and 2.

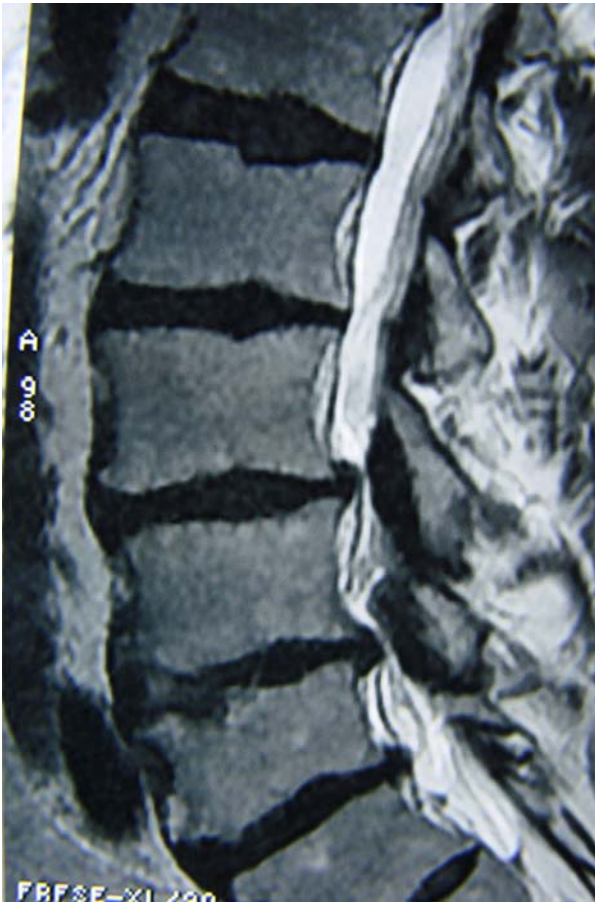

Figure 1: Note the disc degeneration at all lumbar levels, but especially note the spinal stenosis at the L3 thru L5 levels by disc protrusion and ligamentum flavum hypertrophy at the L3 and L4 levels resulting spinal stenosis of the sagittal vertebral canal diameter. There is also small L5-S1 disc protrusion noted.

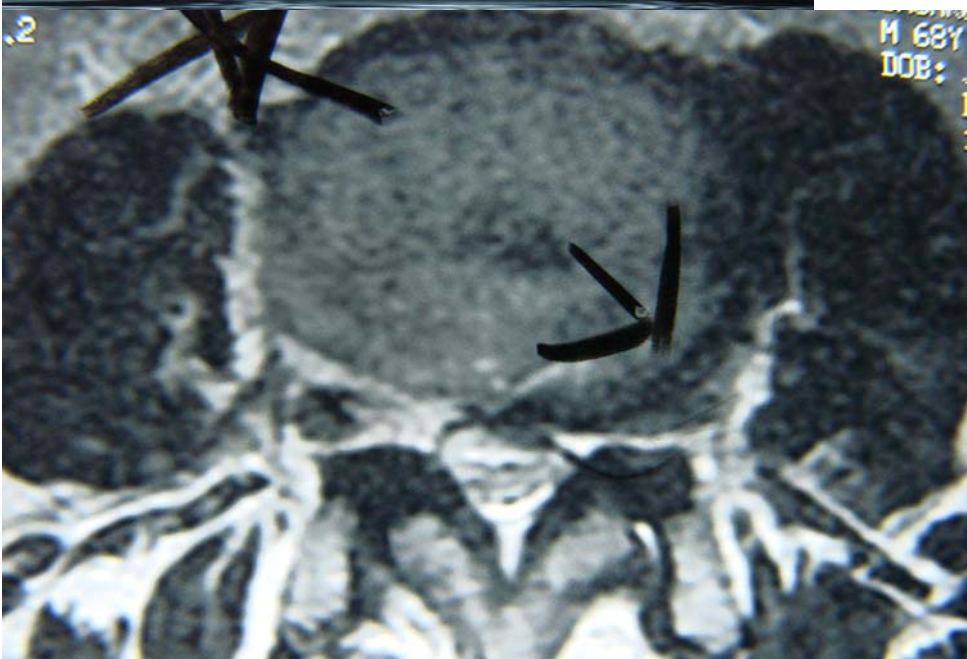

Figure 2: This is the L3-4 disc level. *Note the far lateral disc herniation with endplate hypertrophy extending into the osseoligamentous canal and lateral to the canal creating spinal stenosis.* The L4 nerve root and L3 dorsal root ganglion are compromised. The L4-5 axial images did not reveal such stenosis.

He is referred to a neurosurgeon by his family doctor who recommends surgery to remove the L3-L4 far lateral disc herniation.

Because of cardiovascular disease and its inherent contraindication for surgery, he chose to undergo Cox® flexion distraction and decompression treatment as an alternative to surgery. Our examination revealed that the pain did not extend below the left mid tibia, the quadriceps' strengths were grade 4 of 5, the patella and ankle musculotendinous reflexes were zero bilaterally, ranges of motion were limited to five degrees flexion and extension of the thoracolumbar spine, sitting straight leg raise produced both low back and anterior thigh pain, Kemp's sign was positive bilaterally, Lindner's sign produced both low back and left anterior thigh pain. The patient is markedly over weight and certainly demonstrates sufficient cardiovascular disease to warrant conservative care if possible.

DIAGNOSIS:

L3-4 far lateral disc herniation. No sciatic radiculopathy was present, only left anterior thigh femoral nerve pain. The chosen level of care therefore is L3-L4 which would compromise, with mechanical and chemical inflammation of the L4 nerve root and L3 dorsal root ganglion which would cause the femoral nerve innervation pain of the left anterior thigh.

TREATMENT PLAN & GOAL

The goal of long-y axis and flexion distraction adjusting was to prevent surgery in a cardiovascular compromised patient with the understanding that such surgery might be necessary if one month of care did relieve close to 50% of the leg pain. Daily treatment was recommended for up to one month.

His surgeon was informed of the decision to undergo our care and he is in agreement and is in a watchful waiting mode. The 50% rule was enforced, stating that if he does not show at least 50% improvement within one month of care, surgery will be performed. Within one month of care this patient's pain did exceed 50% relief of pain, and actually the pain had, within three weeks, isolated itself to the anterior left groin and buttock area.

Treatment consisted of Protocol I Cox® Technic decompression flexion distraction of the L3-L4 disc space followed by positive galvanism of the L3-L4 disc herniation followed by tetanizing electrical stimulation to the L3-L4 disc level and the anterior left thigh femoral nerve distribution. Please note that the spinous contact for distraction adjusting was the L3 spinous process. Home care consisted of ice applied two times daily to the L3-4 disc and pelvis to the anterior left thigh. Cox® exercises 1-3 were started on the first day of care for stabilization. He avoids sitting, bending, and lifting.

CLINICAL OUTCOME

The result of this care was marked decreased pain of the left thigh after two treatment sessions as described above. The pain centralized until after four visits the pain was localized to the lumbar spine and groin area. Aggravation by the patient's violation of rules against bending, lifting, and sitting resulted in exacerbation of the left thigh pain after 4 visits. However continued care resulted in total relief of left anterior thigh pain after 8 visits.

By the eleventh visit he could sleep at night.

On the twelfth visit quadriceps strengthening exercises were started.

On the fourteenth visit the relief of pain was 80% with pain only in the left lumbar spine radiating to the pelvis and left hip.

After 17 treatments the back pain was 50% relieved and the left anterior thigh pain 85% absent. He also complained of some right anterior thigh pain which subsided with two visits.

After 20 visits, this patient stated he felt so much better he wanted to stop care. We discouraged this stating discs require 3 months of care to heal and his total treatment time was five weeks. Nevertheless, he was happy with his care and dismissed himself from further care. Everyone was pleased with the outcome – patient, surgeon, chiropractor.

No doubt some of you have noticed that patients often do not grasp the wonderful relief they receive and rather act as if – “What is the big deal, I expected this”. Oh well, let's proceed to compare this case with a non-successful similar case I presented previously.

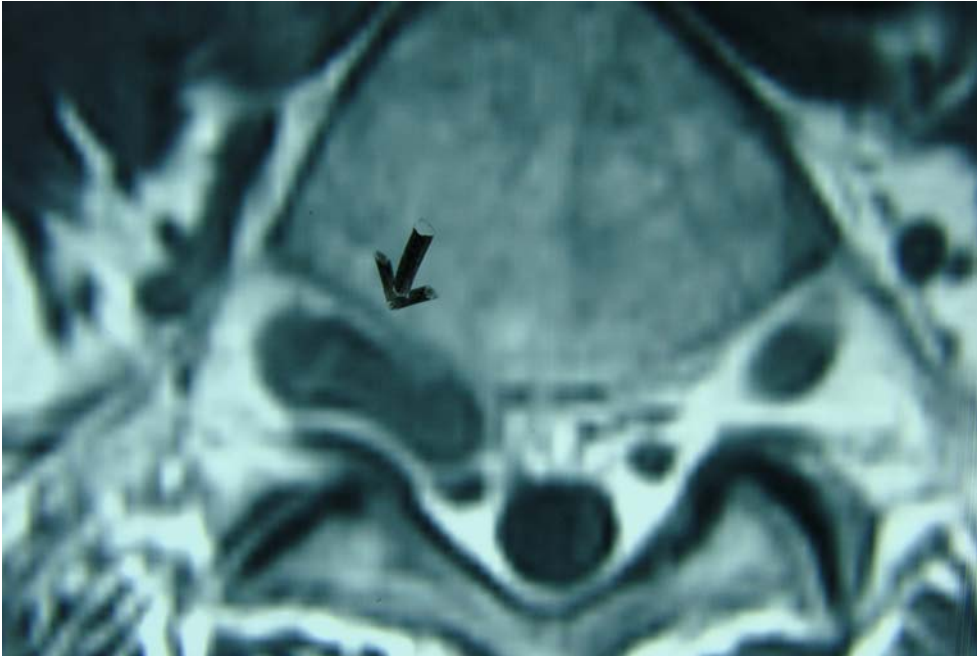
This case also highlights co-management of this case with the neurosurgeon and family doctor as well. Patient outcome is improved by such interdisciplinary care.

CONTRASTING CASE

Now, please contrast this lumbar far lateral L3-4 disc herniation with one that I previously published which did go to surgery. This gives you the opportunity to compare two different discs at the same level, one surgically and one non-surgically successfully treated. Figure 3 shows the large L5-S1 free fragment at the arrow. Flexion distraction and decompression adjusting did not render relief and the progressive motor weakness of dorsi and plantar flexion of the lower extremity prompted surgical relief which gave immediate relief of pain.

The case above is a more contained disc lesion while Figure 3 is a huge free fragment compromising both the S1 nerve root and the L5 dorsal root ganglion resulting progressive motor deficit. You have seen such cases as Figure 3 respond favorably to distraction and flexion distraction manipulation. Why? Perhaps it lies in patient pain tolerance, degree of chemical inflammation of the nerve, uncertainty of the treating doctor continuing care

in the presence of motor or progressive neurological deficit? ***In no way do I infer that disc prolapse is always a surgical case.*** The challenge to determine by other means than just clinical outcome and monitoring of neurological signs what the difficulty factor will be in such cases is needed. Your comments are appreciated.



Respectfully submitted,
James M. Cox, D.C., D.A.C.B.R.

published at www.coxtechnic.com/casereports.asp
March 2008

